

A Study on Observation of Respiratory Ultrasound Plethysmography in Donkeys

Osman GÜNGÖR¹  René VAN DEN HOVEN¹

¹ Department of Small Animals and Horses, Equine Clinic, Section Internal Medicine and Infectious Diseases, University of Veterinary Medicine Vienna, Veterinärplatz 1, 1210 Vienna, AUSTRIA

Article Code: KVFD-2017-17760 Received: 16.03.2017 Accepted: 03.05.2017 Published Online: 06.06.2017

Citation of This Article

Güngör O, van de Hoven R: A Study on Observation of Respiratory Ultrasound Plethysmography in Donkeys. *Kafkas Univ Vet Fak Derg*, 2017 (in Press). DOI: 10.9775/kvfd.2017.17760

Abstract

The respiratory efforts of the thorax and abdominal muscles of donkeys have not adequately been quantified. According to our knowledge, there is no objective, non-invasive monitoring system of lung mechanics in donkeys. This study is the first to describe the nature of thoracoabdominal asynchrony in donkeys. From 22 June 2016 to 19 January 2017 in turn all donkeys (n=18) owned by the Schlosshof GmbH were used for this study. The aim of this study was to analyse the differences of thoracic and abdominal excursions during breathing by using Respiratory Ultrasound Plethysmography (RUP). Synchronisation, rhythm and relative contribution of the thoracic and abdominal muscles were analysed. The final goal was to contribute to a reference data base for diagnostic purposes and find out if RUP could be a simple diagnostic technique for use in the field. The RUP system in its current form is too sensitive to signal noise and generated data are difficult to quantify. Nevertheless, using an alternative algorithm the respiratory strategy of healthy and coughing donkeys appeared different.

Keywords: Donkey pulmonary function, Respiratory ultrasound plethysmography, Thoracic abdominal asynchrony

Eşeklerde Solunum Ultrason Pletismografisinin Gözlemlenmesi Üzerine Bir Çalışma

Özet

Eşeklerin göğüs ve karın bölgelerinin respiratorik eforu yeterince tanımlanmamıştır. Bildiğimiz kadarıyla, eşeklerde akciğer mekaniğinin izlenmesi için objektif, invaziv olmayan bir sistem yoktur. Bu çalışma, eşeklerde torakoabdominal asenkroninin doğasını tanımlayan ilk çalışmadır. Bu amaç için, 22 Haziran 2016'dan 19 Ocak 2017'ye kadar, Schlosshof GmbH'ya ait tüm eşekler (n = 18) kullanılmıştır. Bu çalışmada, solunum sırasındaki göğüs ve karın bölgelerinin hareket farklılıklarının Solunum Ultrason Pletismografisi (RUP) metodu ile analiz edilmesi amaçlandı. Bu amaçla göğüs ve karın bölgelerinin hareketlerinin senkronizasyon, ritim ve bağıl dağılımları analiz edildi. Çalışmanın nihai amacı, referans veri tabanına katkıda bulunmak ve sahada diyagnostik amaçlı basit bir RUP tekniği geliştirmekti fakat, RUP metodunun mevcut haliyle sinyal gürültülerine aşırı duyarlı olduğu ve elde edilen verilerin etkilediği gözlemlendi. Bununla birlikte, sağlıklı ve öksüren eşeklerin solunumları için alternatif algoritma stratejisi uygulanmasıyla da sonuçların farklı olduğu ortaya konuldu.

Anahtar sözcükler: Eşeklerin solunum fonksiyonları, Respirasyon ultrason pletismografisi, Torasik-abdominal asenkroni

INTRODUCTION

Domestic donkeys (*Equus africanus asinus*) descend from African wild ass (*Equus africanus*) populations. The domestication process started probably about 7000 years ago, which is 2000 years earlier than of the horse ^[1,2]. Donkeys were brought to Europe soon after domestication and were already widely distributed throughout the continent in the classical antiquity ^[3]. In Western Europe, donkeys played a role as working animal and for mule

breeding; however, numbers of pure donkeys were modest over the course of time in Western Europe. On the contrary, in South Europe, the Mediterranean, Asia, Africa and America donkeys were or still are common working animals.

Pulmonary disorders are quite prevalent in working donkeys, but suitable diagnostic tools are absent or have not been validated. Of note is the apparently less developed cough reflex of donkeys compared with horses ^[4]. This blunts signs of pulmonary dysfunction and impedes rapid diagnosis.



İletişim (Correspondence)



+43 676 7733131



osmanguengoer@gmail.com

As the donkey is definitely not just a smaller, inferior type of horse^[5], data from equine pulmonary function studies cannot be extrapolated to donkeys. In fact, a study by Delvaux et al.^[6] showed that the breathing mechanics of donkeys compared more closely to bovines than horses. In particular, donkeys have increased respiratory frequency (13-31 breaths/min), increased total pulmonary resistance and a reduced dynamic compliance in comparison with horses.

In a recent UK survey of post mortem findings in 1444 aged donkeys^[7] pulmonary fibrosis was found in more than 35% of all cases, making this the most important lethal respiratory cause. Earlier detection of this disease may reduce animal suffering.

The conventional pulmonary function test (PFT) of horses^[8], is based on the measurement of the trans-thoracal pressure differences between in- and expiration measured in the oesophagus. Therefore, a balloon catheter must be inserted through a short naso-gastric tube via the ventral nasal passage into the thoracic part of the oesophagus. However, this procedure is not always well accepted by horses and thus sedation becomes mostly inevitable. Since sedatives affect the mechanics of breathing^[9], blunting of measurements will occur. Moreover, PFT appeared not a very sensitive tool for detecting smaller changes in diseased airways^[10]. Thus, alternative systems to measure changes in lung function parameters are being developed for horse since more than two decades, but most of them are still under study^[11-15] or interest in the methods was lost.

Konno and Mead^[16] described the lung as a model of two compartments (thorax and abdomen), whereby the movement of the abdomen predominantly reflects the activity of the diaphragm. Elastic bands around thorax or rib cage (RC) and abdomen (ABD) replace the classical body chamber of double-chamber plethysmography^[16]. Induction loop incorporated into these bands function as sensors that detect and quantify movements of the thoracic and abdominal compartments at respiration. This method finds a broad application for the measurement of tidal volume, respiratory rate and monitoring of apnea, hypo- and hyperventilation in man^[17]. Tidal volume measured by the pneumotachograph and by Respiratory Inductive Plethysmography (RIP) differed by only $\pm 6\%$ ^[18,19], indicating that RIP would provide accurate measures of ventilation. However, in a veterinary environment the RIP system was too sensitive for electric interference, therefore a different method, the Respiratory Ultrasonic Plethysmography (RUP), was developed to record changes in thoracic and abdominal changes in circumference^[20].

The aim of the study was to record respiration-induced changes in the RUP signal in order to visualize and calculate normal respiratory patterns of donkeys.

MATERIAL and METHODS

Animals

Twelve healthy and six coughing sedentary pet donkeys aged between 3 and 17 years (see for the gender all other characteristics *Table 1*), all owned by the Schlosshof GmbH were used for this study and allocated in two groups. Before the measurements started, donkeys were accustomed to the measuring procedure. Airway mechanics was measured with the RUP late in the morning (11.00 am) till mid afternoon (3:00 pm). All donkeys were kept out on a grass paddocks and were not fed extra hay or concentrates during the experiments.

Experimental Design

The experimental protocol was approved by the Ethical Review Committee of the Veterinary University of Vienna Animal and by the Austrian Ministry of Education, Sciences and Culture licence number GZ: BMWFW-68.205/0097-WF/V/3b/2016. The study was observational and descriptive statistics were principally used.

Respiratory Ultrasound Plethysmography

The RUP system according to Schramel et al.^[20] was used. Two ethanol filled rubber tubes, placed in the 11th intercostal space and behind the last rib, respectively, were used to measure alterations of abdominal and thoracic circumference during breathing, with 100 Hz

Table 1. Donkeys used in the study

Name	Gender	Age (year)	Chest Width (cm)	Cough	Weight (kg)
Donkey 1	Mare	8	170	1	200
Donkey 2	Mare	9	160	1	182
Donkey 3	Mare	5	155	0	167
Donkey 4	Mare	7	150	0	165
Donkey 5	Mare	5	170	1	180
Donkey 6	Mare	5	155	0	190
Donkey 7	Mare	17	170	1	170
Donkey 8	Mare	13	155	0	170
Donkey 9	Stallion	6	165	0	195
Donkey 10	Mare	6	165	1	190
Donkey 11	Stallion	8	155	0	180
Donkey 12	Mare	9	160	0	175
Donkey 13	Gelding	4	150	0	145
Donkey 14	Mare	3	150	0	146
Donkey 15	Mare	12	160	0	165
Donkey 16	Gelding	4	155	0	140
Donkey 17	Gelding	10	165	1	190
Donkey 18	Stallion	4	170	0	200
Mean		7.5	160		175

sample rate. Data were recorded by the software program BioSystem XA® Version 2.7.9. The data were analysed using Microsoft Office Excel 2016®. The system measures the stretching of compliant liquid - filled rubber tubes with an inner diameter of 5-8 mm that are fastened around the regions of interest. The elastic tubes act as ultrasonic waveguides between an ultrasonic transmitter and receiver at the respective ends. The distance between the tube endings is calculated from the time delay of ultrasonic pulses propagating in the liquid. The tubes are filled with 96% ethanol which has an acoustic velocity of 1207 m second⁻¹ at 25°C. The signal undergoes minimal attenuation even over distances in the magnitude of metres [20].

Special care must be taken not to introduce air bubbles into the fluid. A small electronic processing unit carried by the subject generates signals with a resolution of 0.3 mm and transmits them at sampling rates of 10 or 100 Hz via a Bluetooth link to a computer. Sensor length can be adapted individually within the range of 0.15-2.0 m. Additionally analogue output signals for the two channels use for thoracic and abdominal compartments are available for external data acquisition and comparison with other devices. Prior to measuring, the length of the tubes has to be adapted to the size of the subject to achieve a range of movement within 15% of the total length. The part of the perimeter between transmitter and receiver is completed by means of an adaptable metallic chain preferably placed over the spinal region. This method allows proper pre-tensioning of the waveguides with no slackening during end expiration. The electronics measure the running time of the ultrasonic waves in the ethanol and transfer the data to a laptop via Bluetooth® [20]. In all donkeys, RUP measurements were performed in standing position and during normal spontaneous breathing.

However, the placement of the abdominal band in the 16th and 18th intercostal space [21] gave technical problems due to sliding in the caudal direction (Fig. 1). For this reason, the system had to be adapted such that thoracic and abdominal bands were ventrally fixed with a 20 cm strap to each other (Fig. 1). This strap was fixed to 2 small rigid tubes through which the rubber measuring tubes were passing. This prevented sliding backwards, but may have affected measurements.

Data Handling and Statistical Analysis

Data and waveforms were analysed visually post hoc after processing into graphs with the Microsoft Office Excel 2016 statistical add-in. Thoracic-abdominal asynchrony (TAA) was planned to be measured by Pearson's correlation coefficient from 4 to 6 breath [22], but data deviated too much from the base line that further quantitative analysis with waveform Independent techniques on the unprocessed data was not performed. Using outlier analysis, the data base was cleaned from outliers such that visually reasonable Lissajous loops could be produced. Subsequently a semi-quantification was performed by calculation of the regression of the thoracic signal on the abdominal signal using IBM SSPS Statistic Version 23 software 2016. The arctan of the slope ($\text{tg } \theta$) of the regression line of the data plots was subtracted from 45°, the slope of the perfect synchronisation of abdominal and thoracic excursions, for each individual donkey in order to establish the degree of asynchrony.

Another approach to analyse the 40.000 to 80.000 data points per animal was by selecting a region of 10000 data points per case. These sets were then normalized by their means and standard deviations. Normalised data were further analysed using cross correlation and by calculation of the regression line of xy-plots.

RESULTS

A proportion of the studied donkey occasionally coughed and since these animals were identified as having increased airway resistance, two groups were created for further analysis post hoc.

Many produced curves were too much affected by noise from moving legs, swiping tails or bending of the thorax to enable the detection of 4 to 6 uniform breaths for analysis as was severe base line drift. Fig. 2 shows a suitable curve with a few normal breaths and occasional deep sighs of a quiet and cooperative donkey. The xy-plot of the thoracic and abdominal signals resulted in imperfect Lissajous loops (Fig. 2), but the data cloud enabled calculation of the regression lines.

In this model, the healthy donkey group tended to have greater phase shift, with the thorax lagging behind the



Fig 1. Sliding of the abdominal band towards the prepubic (flank) region causing decrease in circumferential movement. These tapes keep the tubes in a stable state

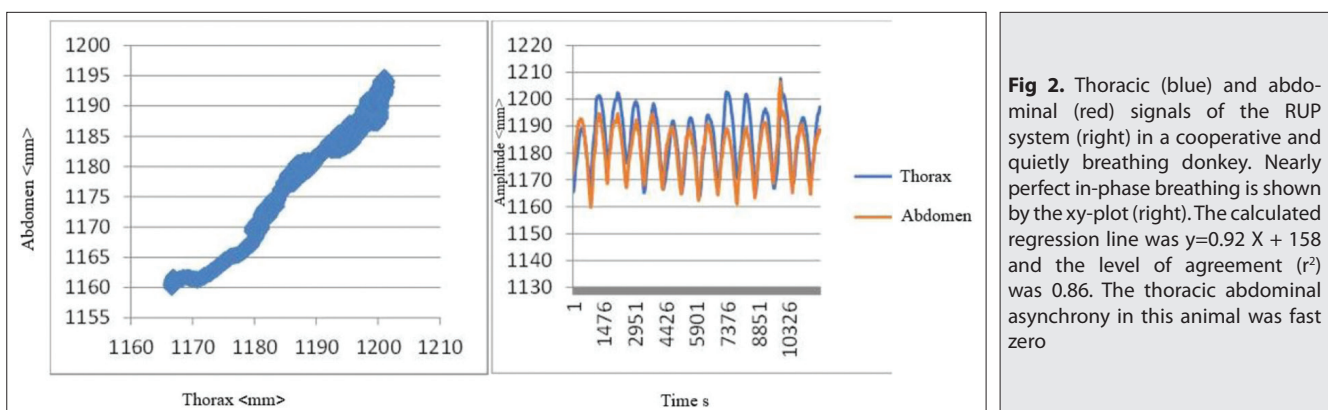


Fig 2. Thoracic (blue) and abdominal (red) signals of the RUP system (right) in a cooperative and quietly breathing donkey. Nearly perfect in-phase breathing is shown by the xy-plot (right). The calculated regression line was $y=0.92 X + 158$ and the level of agreement (r^2) was 0.86. The thoracic abdominal asynchrony in this animal was fast zero

abdomen movements than with the coughing animals but the differences were not statistically significant ($P=0.96$). So were the cross-correlation coefficient differences insignificant ($P=0.55$).

The second analytical approach, which is waveform independent, appeared more useful with large data sets in quickly finding phase shifts between thorax and abdomen excursions. On average, abdomen activity started before thorax activity in both groups as in the first model, but in the coughing donkeys, the lag between abdomen activity and thoracic activities was only 12 msec compared to the 23 msec of the healthy donkeys. However, the difference was not statistically significant ($P=0.96$).

DISCUSSION

The RUP system has been developed by Schramel [20,22] and validated as an alternative to the RIP system that appeared too sensitive to environmental electric noise. Yet, there are still conditions that decrease the accuracy of the device. Firstly, belts should not be placed too tight causing the actual cross sectional change of the chest or abdomen to be restricted and thus data will not reflect the patient's true breathing efforts. On the other hand, if belts are placed too loosely, the belts will slide to pre-pubic region in donkeys where there is less abdominal distension and hence weak signals are produced. In the horse the thoracic band is placed in the 11th intercostal space, which was also feasible with donkeys. Some authors prefer to position the thoracic band in the 6th intercostal space accepting small excursions of the thorax thereby offering larger excursion for specify [23].

Thoraco-abdominal asynchrony (TAA) is defined as the no coincident motion of thorax and abdomen and is considered as relevant clinically. TAA may be calculated using the Lissajous approach [24], but in case of much signal noise, the calculation of cross correlation coefficient $\rho_{xy}(\tau)$ has been shown to be a better approach [25]. In the case of sinusoidal signals, θ is independent of the choice of reference points for its calculation, but the respiratory signals may not be sinusoidal in shape [26]. Assessing start

and stop of inspiration and expiration, merely from the RIP sum signal, is difficult. Especially in the case of severe asynchrony, the start of inhalation cannot be inferred from the RIP or RUP signals alone. In man, therefore an external source for respiratory timing is used [27]. This alone makes RUP unsuitable for fast and simple diagnostics in the field.

For the analysis of data in this study the $\rho_{xy}(\tau)$ approach appeared to produce the better results. The cross-correlation analysis indicated that in donkeys on average the thoracic activity lags behind the abdominal activity and in the coughing, donkeys this lag period on average seems smaller than in healthy animals suggesting that the thoracic activity attributes more early in the respiratory effort as has been shown to occur in horses with heaves [19].

It is still unclear how to interpret changes in TAA. The TAA pattern in infants with airway obstruction and/or lung restriction is such that the on-inspiration thorax lags behind the abdomen [27]. In contrast to diseased children, the healthy horses show the same pattern with none to a minimal phase shift, with the thorax lagging behind the abdomen during the onset of inspiration. On the other hand, horses with heaves have a phase shift that is characterized by the thorax leading in sequence before the abdomen. This pattern was unique to heaves. It was most pronounced in a group of horses with the abdominal paradox [19]. Furthermore, Haltmayer et al. [28] found that horses affected by a pulmonary disorder showed a lower degree of TAA than healthy horses, which agrees with our finding with the RUP in coughing donkeys. The RIP and possibly the RUP system too appear not that suitable for the diagnosis of pulmonary problems in a quick and simple way. So were Miller et al. [29] not able to show a significant correlation between the degree of change in resistive pulmonary load on foals and the degree to which phase angle was altered. Although RIP variables changed markedly with fixed upper airway resistive loading, the degree to which they changed was erratic and therefore not useful for grading these obstructions. Hoffman et al. [19] reported that RIP variables were insensitive measures of bronchoconstriction. RAO horses during exacerbation have severely increased θ with abdomen consistently

lagging behind the thorax, and a reduced contribution of the abdomen to ventilation [19]. This was pattern in contrast with the breathing strategy of healthy donkeys and most of the coughing animals.

Although it was possible to find a decrease in phase shift between the coughing and healthy donkey group, the RUP system is too sensitive for signal noise and therefore not specific enough to simply detect subtle changes in breathing pattern suggestive for pulmonary dysfunction in donkeys. Similarly, the RIP system also largely appeared unsuitable for diagnosing foal's respiratory disorders [29]. Therefore, measuring TAA in Donkeys with RIP instead of RUP likely would not have improved the outcome of the study.

AUTOR'S DECLARATION OF INTEREST

The authors report no conflicts of interest.

ETHICAL ANIMAL RESEARCH

The experimental protocol was approved by the Ethical Review Committee of the Veterinary University of Vienna and by the Austrian Ministry of Education, Sciences and Culture, licence number: (GZ): BMWFW-68.205/0097-WF/V/3b/2016

ACKNOWLEDGEMENT

We would like to thank Dipl. Ing., Dr. Med. Vet. Johannes Peter Schramel for his dedicated help and for his support.

REFERENCES

- Beja-Pereira A, England PR, Ferrand N, Jordan S, Bakhiet AO, Abdalla MA, Mashkour M, Jordana J, Taberlet P, Luikart G:** African origins of the domestic donkey. *Science*, 304, 1781, 2004. DOI: 10.1126/science.1096008
- Ludwig A, Pruvost M, Reissmann M, Benecke N, Brockmann GA, Castaños P, Cieslak M, Lippold S, Llorente L, Malaspinas AS, Slatkin M, Hofreiter M:** Coat color variation at the beginning of horse domestication. *Science*, 324, 485, 2009. DOI: 10.1126/science.1172750
- Yanes García JE:** Antecedentes históricos. In, Alimentación P (Ed): Ministerio de Agricultura. Razas asnales autóctonas españolas. Madrid, Spain; 39-97, 2005.
- Thiemann AK:** Respiratory disease in the donkey. *Equine Vet Educ*, 24, 469-478, 2012. DOI: 10.1111/j.2042-3292.2011.00292.x
- Burnham SL:** Anatomical differences of the donkey and mule. *Am Assoc Equine Pract*, 48, 102-109, 2002.
- Delvaux V, Kirschvink N, Amory H, Busoni V, Art T, Lekeux P:** Spécificités de la fonction cardiorespiratoire de l'âne (*Equus asinus*). *Prat Vet Equine*, 33, 21-28, 2001.
- Morrow LD, Smith KC, Piercy RJ, du Toit N, Burden FA, Olmos G, Gregory NG, Verheyen KLP:** Retrospective analysis of post-mortem findings in 1,444 aged donkeys. *J Comp Pathol*, 144, 145-156, 2011. DOI: 10.1016/j.jcpa.2010.08.005
- Derksen FJ, Robinson NE:** Esophageal and intrapleural pressures in the healthy conscious pony. *Am J Vet Res*, 41 (11): 1756-1761, 1980.
- Lavoie JP, Pascoe JR, Kurpershoek CJ:** Effect of head and neck position on respiratory mechanics in horses sedated with xylazine. *Am J Vet Res*, 53 (9): 1652-1657, 1992.
- Robinson NE, Olszewski MA, Boehler D, Berney C, Hakala J, Matson C, Derksen FJ:** Relationship between clinical signs and lung function in horses with recurrent airway obstruction (heaves) during a bronchodilator trial. *Equine Vet J*, 32 (5): 393-400, 2000.
- Desager KN, Buhr W, Willemen M, Van Bever HP, De Backer W, Vermeire PA, Landser FJ:** Measurement of total respiratory impedance in infants by the forced oscillation technique. *J Appl Physiol*, 71 (2): 770-776, 1991.
- Hoffman AM:** Clinical application of pulmonary function testing in horses. In, Lekeux P (Ed): Equine Respiratory Diseases International Veterinary Information Service. Ithaca NY, <http://www.ivis.org>. Last update: 2002-10-07, Accessed: 26.03.2014.
- Klein C, Smith HJ, Reinhold P:** The use of impulse oscillometry for separate analysis of inspiratory and expiratory impedance parameters in horses: Effects of sedation with xylazine. *Res Vet Sci*, 80, 201-208, 2006. DOI: 10.1016/j.rvsc.2005.06.005
- MacLeod D, Birch M:** Respiratory input impedance measurement: Forced oscillation methods. *Med Biol Eng Comput*, 39 (5): 505-516, 2001.
- Winkler J, Hagert-Winkler A, Wirtz H, Hoheisel G:** Modern impulse oscillometry in the spectrum of pulmonary function testing methods. *Pneumologie*, 63, 461-469, 2009. DOI: 10.1055/s-0029-1214938
- Konno K, Mead J:** Measurement of the separate volume changes of rib cage and abdomen during breathing. *J Appl Physiol*, 22 (3): 407-422, 1967.
- Adams JA, Zabaleta IA, Stroh D, Sackner MA:** Measurement of breath amplitudes: Comparison of three noninvasive respiratory monitors to integrated pneumotachograph. *Pediatr Pulmonol*, 16, 254-258, 1993. DOI: 10.1002/ppul.1950160408
- Hoffman A, Kuehn H, Riedelberger K, Kupcinskas R, Miskovic MB:** Flowmetric comparison of respiratory inductance plethysmography and pneumotachography in horses. *J Appl Physiol*, 91 (6): 2767-2775, 2001.
- Hoffman AM, Oura TJ, Riedelberger KJ, Mazan MR:** Plethysmographic comparison of breathing pattern in heaves (recurrent airway obstruction) versus experimental bronchoconstriction or hyperpnea in horses. *J Vet Intern Med*, 21, 184-192, 2007. DOI: 10.1111/j.1939-1676.2007.tb02945.x
- Schramel J, Hoven Rvd, Moens Y:** *In vitro* validation of a new respiratory ultrasonic plethysmograph. *Vet Anaesth Analg*, 39, 366-372, 2012. DOI: 10.1111/j.1467-2995.2012.00723.x
- Deaton CM, Deaton L, Jose-Cunilleras E, Vincent TL, Baird AW, Dacre K, Marlin DJ:** Early onset airway obstruction in response to organic dust in the horse. *J Appl Physiol*, 102, 1071-1077, 2007. DOI: 10.1152/jappphysiol.00264.2006
- Schramel JP:** Ultraschallplethysmographie beim Pferd. *Thesis*, Vet. Med. Univ. Wien, pp.75, 2008.
- Behan AL, Hauptman JG, Robinson NE:** Telemetric analysis of breathing pattern variability in recurrent airway obstruction (heaves)-affected horses. *Am J Vet Res*, 74, 925-933, 2013. DOI: 10.2460/ajvr.74.6.925
- Agostoni E, Mognoni P:** Deformation of the chest wall during breathing efforts. *J Appl Physiol*, 21 (6): 1827-1832, 1966.
- Prisk GK, Hammer J, Newth CJ:** Techniques for measurement of thoracoabdominal asynchrony. *Pediatr Pulmonol*, 34, 462-472, 2002. DOI: 10.1002/ppul.10204
- Hammer J, Newth CJ, Deakers TW:** Validation of the phase angle technique as an objective measure of upper airway obstruction. *Pediatr Pulmonol*, 19 (3): 167-173, 1995.
- Strömberg NOT, Nelson N:** Thoracoabdominal asynchrony in small children with lung disease - methodological aspects and the relationship to lung mechanics. *Clin Physiol*, 18, 447-456, 1998. DOI: 10.1046/j.1365-2281.1998.00118.x
- Haltmayer E, Reiser S, Schramel JP, van den Hoven R:** Breathing pattern and thoracoabdominal asynchrony in horses with chronic obstructive and inflammatory lung disease. *Res Vet Sci*, 95, 654-659, 2013. DOI: 10.1016/j.rvsc.2013.06.008
- Miller C, Hoffman AM, Hunter J:** Thoracoabdominal asynchrony failed to grade airway obstructions in foals. *J Appl Physiol*, 88 (6): 2081-2087, 2000.