

Translatory Facet Joint Locking in a Cat (Bir Kedide Translasyonel Facet Eklem Kilitlenmesi)

Hakan SALCI ¹  Hilal ÇEŞME ¹

¹ Department of Surgery, Faculty of Veterinary Medicine, Uludağ University, TR-16059 Bursa - TURKEY

Article Code: KVFD-2017-17842 Published Online: 21.04.2017

Citation of This Article

Salcı H, Çeşme H: Translatory facet joint locking in a cat. *Kafkas Univ Vet Fak Derg*, 23 (4): 681-682, 2017. DOI: 10.9775/kvfd.2017.17842

Dear Editor,

Spinal trauma resulting from the traffic accidents is a common etiology in cats and dogs. Severity of the trauma may cause to traction, compression, extension, flexion and torsion causing vertebral column injury. These forces act on the vertebral column and lead to different types of fracture and luxation [1]. Anatomically, the facet joints limit the segmental range of motion, and absorb the energy that results from the ventrally directed shearing forces [2,3].

The facet joints together with ligaments determine the direction and degree of displacement of the vertebrae one to another [3]. A locked facet joint is a type of facet joint dislocation [2,4]. This luxation causes by a skipping of the cranial articular process over the superior articular process of the vertebra below and becomes locked in the position [4]. The facet joint locking is a spinal cord deformity that it develops after a significant trauma, which is encountered either "rotatory" or "translator" locking in humans [2]. A plan radiograph is almost sufficient for the diagnosis but computed tomography and magnetic resonance imaging may be performed [2,3]. The treatment methods applied may be conservative (provocative mobilization with movements) or operation; however, the conservative method is less effective than surgery [2]. In the literature, acute cervical and lumbar facet joint locking is reported in humans, but thoracic facet joint locking is not familiar described because of rib cage coupling [4]. According to our knowledge, this condition has not been reported in companion animals yet; thus, we aimed to report radiological and surgical findings of a translatory facet joint locking in a cat.

A 7 month-old, female, domestic shorthair cat was presented to Uludag University, Faculty of Veterinary Medicine, Department of Surgery Clinics after a traffic

accident. Clinically, vital parameters of the cat were normal; however, she had minimal hind-limb sensation to the reflexes of the skin pinches, which was suspected as upper motor neuronal lesion, and decreased motor reflexes (patellar, pedal reflexes etc) due to lower motor neuronal lesion, as well. In addition, when the cat hold up by an assistant, it was seen that the left front limb had second degree lameness and the cat was not bearing her weight on this leg, compared to right one. Palpation of this leg revealed a scapular fracture, and palpation of the vertebral column determined an irregularity of the spinal process on the cranial part of thoracic vertebrae. The other orthopedic and neurologic examination findings were normal. Lateral and ventrodorsal radiographes pointed out a minimal dislocated scapular fracture and the dorsal dislocation of third thoracic vertebra at the level of facet joints. The caudal articular process of the facet joint of 3rd vertebra was jumping of the cranial articular process and the superior articular process of the vertebra was below and become locked. There was no rotational vertebra at the dislocation site, as well (Fig. 1).

Based on the clinical and radiological examination results, the facet joint locking and a scapular fracture were diagnosed in the cat. Due to conservative treatments (flexional and extensional vertebral movements), the luxation was not replaced; thus operation was decided in this cat by the permission of the owner.

Sedation and induction of the cat was provided with xylazine HCl (1 mg/kg, im) and ketamine HCl (8 mg/kg, im) respectively. After endotracheal intubation, general anesthesia was applied with 2% concentration of isoflurane. The cat was positioned sternoabdominally, and operation site was prepared for aseptic surgery. The dorsal midline incision and dissections were performed to expose the dislocated area. It was evident that facet joints of 3rd thoracic vertebra were out of the joint, and



İletişim (Correspondence)



+90 224 2940841



hsalci@uludag.edu.tr

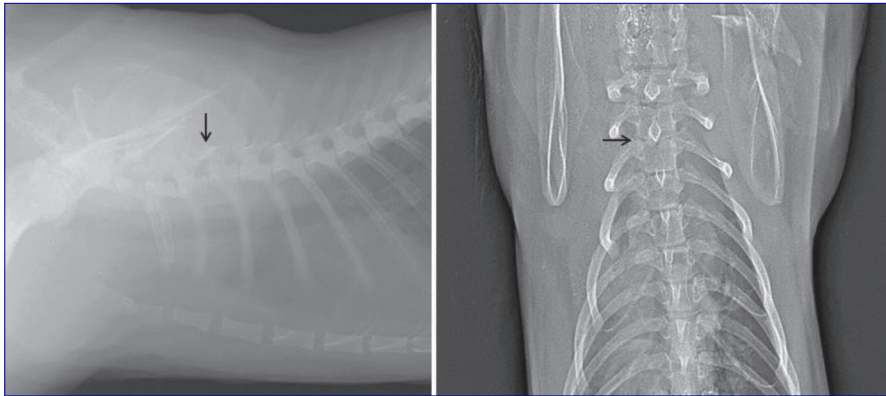


Fig 1. The views of dorsal dislocation of 3rd thoracic vertebra at the level of facet joints (arrows) in lateral and ventrodorsal radiographies

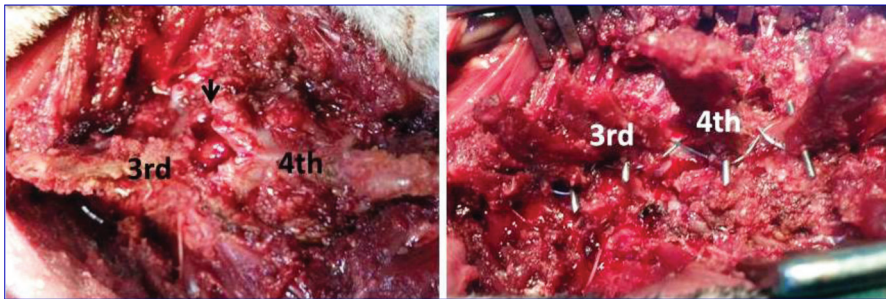


Fig 2. In the intraoperative views, left figure shows dorsal luxation parts of facet joints (arrow) following dissection and minimal dorsal laminectomy, and right figure demonstrates applied stabilization technique between the vertebrae

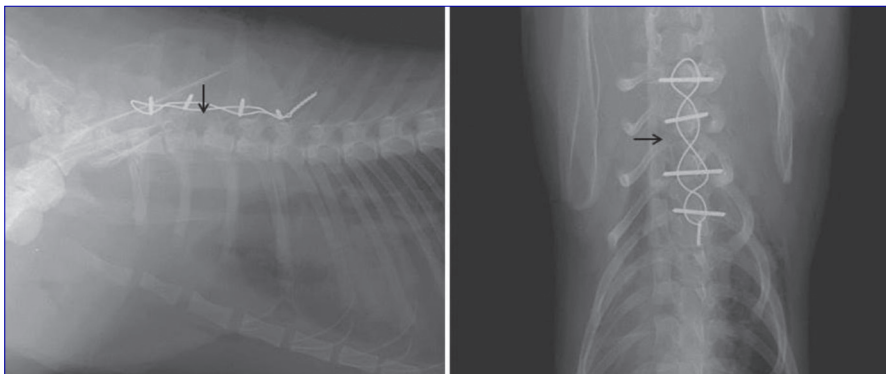


Fig 3. These views present repositioning of the intervertebral space (arrows) and vertebral column in the lateral and ventrodorsal radiographs

3rd vertebra was luxated dorsally. A minimal dorsal laminectomy and a conventional modified fixation technique were performed (Fig. 2). As a stabilization technique, a kirschner pin was transversally inserted to spinal processes of 1st, 2nd, 3rd and 4th thoracic vertebra, and then a tension band was applied between these pins, which were passing to spinal processes of the effected thoracic vertebra from 1st to 4th (Fig. 3). Spinal cord injury was not determined during surgery. Surgical incisions were closed routinely. Postoperative radiographs showed that the luxation part of the vertebral column was placed in normal location and fixation was ensured. At postoperative period, cefazolin Na (20 mg/kg, im, bid) and tolfenamic acid (2 mg/kg, sc, qd) were administered as antibiotic and analgesic agents, respectively. The bandage was applied to left extremity for scapular fracture and routine controls were planned. The cat was discharged.

REFERENCES

1. Jeffery ND: Handbook of Small Animal Spinal Surgery. 111-127, W.B. Saunders, London, 1995.
2. Shaffrey CI: Facet joint locking. *J Neurosurg Spine*, 14, 1-2, 2011.
3. Bergnut N, Forterne F, Levine JM, Lasser SD, Fingerth JM: Compression between biped (human) and quadruped (canine/feline) intervertebral disc disease. In, Fingerth JM, Thomas WB (Eds): *Advances in Intervertebral Disc Disease in Dogs and Cats*. 14-22, Willey-Blackwell, USA, 2015.
4. Horton SJ: Acute locked thoracic spine: Treatment with a modified SNAG. *Manual Therapy*, 7(2): 103-107, 2002. DOI: 10.1054/math.2002.0456