

## Trancient Horner's Syndrome as a Result of Nasopharyngeal Polyp Traction-Avulsion in a Cat <sup>[1]</sup>

F. Eser ÖZGENCİL <sup>1</sup>  Çağrı GÜLTEKİN <sup>1</sup> Gökhan ULUKAN <sup>1</sup>

<sup>[1]</sup> Presented as poster in International Veterinary Medicine Spring Congress (27 -30 March, 2017, Antalya/Turkey)

<sup>1</sup> Department of Surgery, Faculty of Veterinary Medicine, Near East University, Nicosia, Turkish Republic of North Cyprus

Article Code: KVFD-2016-17136 Received: 24.11.2016 Accepted: 09.04.2017 Published Online: 14.04.2017

### Citation of This Article

Özgenicil FE, Gültekin Ç, Ulukan G: Trancient Horner's Syndrome as a result of nasopharyngeal polyp traction-avulsion in a cat. *Kafkas Univ Vet Fak Derg*, 23 (4): 669-671, 2017. DOI: 10.9775/kvfd.2016.17136

### Abstract

A 5-month old, female, half-breed Russian Blue cat was admitted to Animal Hospital of Near East University with a complaint of noisy breathing. Nasopharynx examination revealed a mass in the left region. The findings of external ear canal and tympanic membrane, and cavum tympani were normal according to video otoscopic examination and direct tympanic bulla radiography, respectively. Mass was removed by traction-avulsion and histopathological examination showed chronic inflammatory polyp. Horner's syndrome was recovered within a month in post-operative period.

**Keywords:** *Nasopharyngeal polyps, Feline inflammatory polyps, Horner's syndrome*

## Bir Kedide Nasofarengal Polip Traksiyon-Avulziyonu Sonucu Gelişen Geçici Horner Sendromu

### Özet

Yakın Doğu Üniversitesi Hayvan Hastanesi'ne, gürültülü soluma şikayeti ile gelen 5 aylık, dişi, Russian Blue melezi bir kedide yapılan farens muayenesi sonucu sol nazofarengal bölgede kitle tespit edildi. Videootoskopik muayenede dış kulak yolu ile kulak zarının, direkt bulla radyografisinde ise kavum timpaninin normal olduğu belirlendi. Kitle; traksiyon-avulziyon yöntemi ile alındı ve yapılan histopatolojik muayenede kronik inflamatorik polip olduğu belirlendi. Postoperatif 1. gün gelişen Horner sendromunun, topikal sempatomimetik midriyatik kullanımı ile bir ay içinde düzeldiği gözlemlendi.

**Anahtar sözcükler:** *Nazofarengal polipler, Kedi yangısal polipleri, Horner sendromu*

### INTRODUCTION

Non-carcinogenic feline inflammatory polyps (FNPs) are benign fibrous masses that are invasively pedunculated with inflammatory cells. It is reported that middle ear and nasopharynx FNPs in cats originate from tympanic bulla or Eustachian tube epithelium lines <sup>[1,2]</sup>. They may either reach pharynx via the eustachian tube, or the external ear canal with rupture of the tympanic membrane <sup>[2]</sup>. The dominant idea is that its etiology has infection or congenital reasons <sup>[3]</sup>. Due to the anatomical different in feline middle ear, it is known that there is frequently Horner's syndrome and rarely vestibular syndrome taking place following removal of polyps originated in the middle ear via the method of traction and/or ventral bulla osteotomy (VBO). It was

reported that excessive curettage of promontory may lead to this in VBO <sup>[4]</sup>. In treatment of FNPs, primary recommendation is traction and avulsion of the polyp from the ear canal or in the nasopharyngeal way, where hemorrhage is minimal under anesthesia. It was reported that there is a 50% change of polyp relapse this way. There is a dominant consideration that postoperative medical therapy increases the success rate <sup>[2,5]</sup>. Other complications include vestibular disturbances, polyp re-growth, otitis media, hemorrhage, wound drainage, hypoglossal nerve damage, damage to auditory ossicles and vascular structures, and facial nerve paralysis <sup>[6]</sup>.

Publication of the case presentation was approved because of beneficial effect of topical sympathomimetic



### İletişim (Correspondence)



+90 533 8313883



eser.ozgenicil@neu.edu.tr

mydriatic using in the treatment of Horner's syndrome after FNPs removed.

## CASE HISTORY

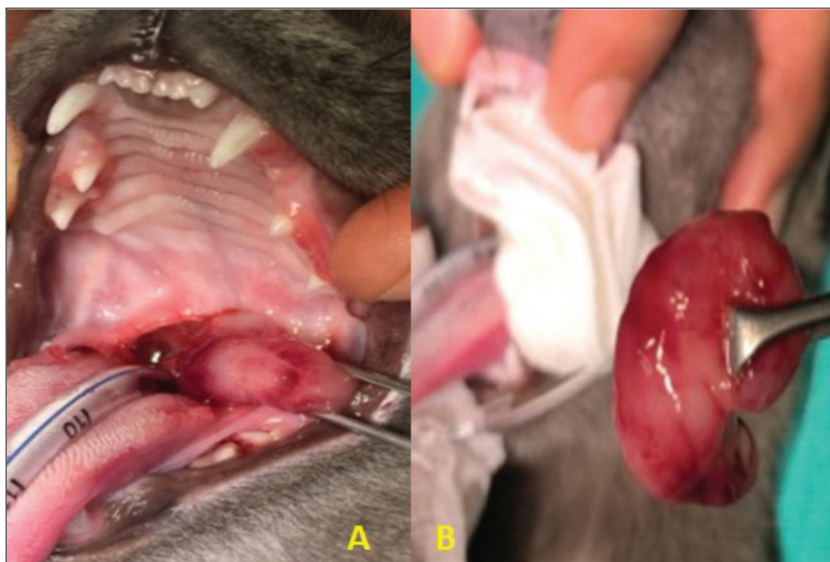
A mass was detected on the left nasopharyngeal region as a result of the pharynx examination on a Russian Blue hybrid, 5-month-old, female cat brought to YDU Veterinary Hospital with complaints of rough heavy breathing. Normal signs were found in the external ear canal and the ear drum with the video otoscopy examination, and in the cavum tympani with the direct bulla radiography. Following the Xylazine HCl (Vetaxyl 20 mg, Vetagro, 2 mg/kg IM) premedication; induction was achieved with Ketamine HCl (10% Ketamine, Dutchfarm, 10 mg/kg IM). The polyp was removed with traction avulsion after endotracheal intubation (Fig. 1).

In the histopathologic examination, it was found that this was a chronic inflammatory polyp. Phenylephrine


HCL (2.5% Mydrfrin ophthalmic solution, Alcon, 3x2 drops) was given to fix the Horner's syndrome that occurred following the traction-avulsion of the polyp (Fig. 2), while Methylprednisolone acetate (Prednol tablet, Mustafa Nevzat, 2 mg/kg/day orally for 1 month) was given to prevent relapse of the polyp. It was observed that the Horner's syndrome that developed in the 1st operative day was fixed in a period of 1 month (Fig. 3). The results of the hemogram, blood count, blood biochemistry, urine analysis, feline leukemia virus and feline immunodeficiency virus tests on the cat were in normal ranges.

## DISCUSSION

It is reported that inflammatory cat polyps are usually seen under the age of 2 years unilaterally, there is no tendencies based on breed or sex<sup>[2,3]</sup> and these have pink, peduncular and ulcerous macroscopic appearances<sup>[5]</sup>. In the pharynx examination of our case, it was observed that the polyp was on one side, it was ulcerous and had a chronic inflammatory structure.



**Fig 1.** Removal of nasopharyngeal polyp by traction-avulsion (A). Inflammatory and ulcerated macroscopic view of polyp (B)



**Fig 2.** Post-operative Horner's syndrome in the left eye (ptosis, miosis, enophthalmos, protrusion of palpebra tertia)

Cats with FNPs may show symptoms of otitis externa and/or otitis media, as well as symptoms of upper airway obstruction<sup>[1]</sup>. It is known that symptoms include heavy breathing, change of voice, nasal discharge, difficulty in swallowing, nutation, sneezing, vestibular signs, Horner's syndrome and blood-containing discharge from the external ear canal<sup>[2,5]</sup>. It is reported that the best diagnostic plan is oropharyngeal examination under anesthesia<sup>[2,7]</sup>, otoscopic examination<sup>[5]</sup>, and lateral radiography or computer tomography where soft tissue opacity may be monitored in the nasopharynx<sup>[2,8]</sup>. Diagnosis of inflammatory polyp was made after the pharynx and histopathology examination on our case with difficulty in swallowing and heavy breathing complaints. Ear canal video otoscopy and bulla radiography were carried out for the differential diagnosis of otitis media. Taking the factor of age into account, nasopharynx or middle ear originated polyp cases may be considered in cats with complaints of upper airways, otitis externa and otitis media. It should be considered to take bulla radiography with the purpose of examining the connection between the external ear canal and the middle ear via video otoscopy in addition to pharynx examination. These methods are required in cases where the advanced diagnosis of CT is not available. It is reported that rate of relapse in FNPs is 50%. In their



**Fig 3.** Recovery of the Horner's syndrome within one month post-operatively

operative treatment, it is recommended to perform traction and avulsion of the polyp through the ear canal or in a nasopharyngeal way. It was reported that corticosteroid (1 to 2 mg/kg/day for 14 days) in the postoperative period reduces relapse in cats by 11% [2,5]. VBO was recommended for operative treatment of polyps that originate from the middle ear [3]. Positive outcomes were obtained from the corticosteroid application following the traction-avulsion method, and no mid-term relapse was encountered.

It is known that the most important postoperative complication that may follow removal of polyps is temporary Horner's syndrome by 40%, this is caused by the damage on the oculosympathetic tract during operation, and the complication is solved in weeks or months in most cases [2,3,5]. It was reported that the success rate of the traction-avulsion method cats with only nasopharyngeal polyps is four times higher than those with ear canal polyps [9]. It was reported that 25% of cats that are affected by temporary Horner's syndrome in the postoperative period are affected long-term. In another study, in polyps removed with the method

of traction-avulsion only, not only were relapses seen, but also the Horner's syndrome that occurred was solved in 7-10 months [7]. In the case, there were typical sympathetic denervation signs of Horner's syndrome (ptosis, miosis, enophthalmos, and elevation of the third eyelid), and it was thought that application of topical phenylephrine contributed to the recovery in a short time like 1 month.

As a result, it was concluded that combining the traction-avulsion method with VBO in polyps originating from the middle ear increased success, and usage of the traction-avulsion method by itself in polyps with no connection to the middle ear is sufficient, bloodless method and a technique that leads to minimal tissue damage. It was concluded that success rate is increased by making the diagnosis after bulla radiography, video otoscopy and pharynx examination in cases where CT is not available for dismissing the possibility of middle ear connection, usage of sympathomimetic mydriatics in treatment of Horner's syndrome in the postoperative period, and postoperative corticosteroid usage in case of relapse.

## REFERENCES

- MacPhail CM, Innocenti CM, Kudnig ST, Veir JK, Lappin MR:** Atypical manifestations of feline inflammatory polyps in three cats. *J Feline Med Surg*, 9, 219-25, 2007. DOI: 10.1016/j.jfms.2006.11.004
- Donnelly KE, Tillson DM:** Feline inflammatory polyps and ventral bulla osteotomy. *Comp Cont Ed Vet*, 446-541, 2004.
- Pope ER, Constantinescu GM:** Feline respiratory tract polyps. In, Bonagura J (Ed): *Kirk's Current Veterinary Therapy*. 13<sup>th</sup> edn., 794-796, WB Saunders, Philadelphia, 2000.
- Little CJ, Lane JG:** The surgical anatomy of the feline bulla tympanic. *J Small Anim Pract*, 27, 371-378, 1986. DOI: 10.1111/j.1748-5827.1986.tb02150.x
- Muilenburg RK, Fry TR:** Feline nasopharyngeal polyps. *Vet Clin North Am: Small Anim Pract*, 32, 839-849, 2002. DOI: 10.1016/S0195-5616(02)00024-4
- Faulkner JE, Budsberg SC:** Results of ventral bulla osteotomy for treatment of middle ear polyps in cats. *JAVMA*, 26, 496-499, 1990.
- Bradley RL, Noone KE:** Nasopharyngeal and middle ear polypoid masses in five cats. *Vet Surg*, 14, 141-144, 1985. DOI: 10.1111/j.1532-950X.1985.tb00844.x
- Kapatkin AS, Matthiesen DT, Noone KE, Church EM, Scavelli TE, Patnaik AK:** Results of surgery and long-term follow-up in 31 cats with nasopharyngeal polyps. *JAAH*, 26, 387-392, 1990.
- Anderson DM, Robinson RK, White RAS:** Management of inflammatory polyps in 37 cats. *Vet Rec*, 147, 684-687, 2000. DOI: 10.1136/vr.147.24.684